EXAM COMMITTEE

15th Batch NEU-241 Midterm

Disclaimer: Despite our best efforts, we cannot guarantee the absolute accuracy of our answers. For complete certainty, please refer back to the lectures. We sincerely apologize for any mistakes.

Do not share the document with the doctors!

Q1: A patient with severe deficiency of vitamin B12 will present with degeneration and demyelination of which one of the following spinal cords tracts?

A. Lateral spinothalamic tract
B. Spinotectal
C. Anterior spinothalamic tract
D. Lateral corticospinal tract

Ans: D

Q2: Which of the following somatosensory receptors are particularly known for exhibiting slow adaptation?

A. Hair receptors
B. Meissner's corpuscles
C. Pacinian corpuscles
D. Merkel cells

Ans: D

Q3: Damage to the upper part of right nucleus solitarius will present with which one of the clinical signs?

A. Loss pain sensations from the right posterior ⅓ of tongue
B. Loss of taste sensations from right anterior 2/3 of tongue
C. Loss of vibration sense from the left side of the body

Ans: B

Q4: Corticospinal tract fibres pass through which one of the following parts of brainstem?

A. Tegmentum of pons
B. Crus cerebri
C. Lateral medulla

Ans: B

Q5: (A long case about a 65-year-old with various problems including Hyperlipidemia and DM). Evaluations show that he has left-right disorientation and is unable to carry out simple calculations, read or write. Which of the following brain areas is most likely affected in this patient?

A. Midbrain at level of superior colliculus
B. Bilateral occipital lobes
C. Dominant parietal lobe

Ans: C

Q6: A patient with a brainstem stroke presents with right eye deviated medially and spastic paralysis of left side of the body. Which one of the following parts of the brainstem is involved?

A. Right medial pons
B. Left lateral medulla.
C. Left lateral pons.
D. Left medial medulla.

Ans: A

Q7: A patient suffered a brainstem stroke. He presents with loss of pain sensations on the right side of the body and the left side of the face. He also presents with flattening of the left side palatal arch. Which one of the following parts of the brainstem is involved?

A. Right medial pons
B. Left lateral pons.
C. Left lateral medulla
D. Right medial medulla

Ans: C

Q8: (A long scenario about a patient who suffered a stroke) Unfortunately, he died the next day. An autopsy was performed. Which one of the following lesions is shown in the attached microscopic figure (H & E stain) from his brain?

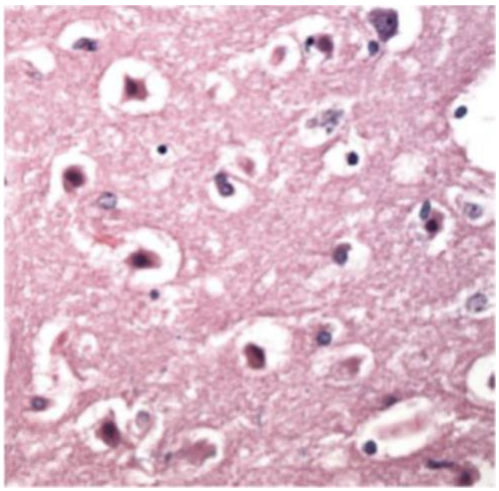

A. Red neurons
B. Diffuse axonal injury
C. Neurodegeneration

Ans: A

Q9: When the nerve is stimulated the vesicles with neurotransmitters fuse with the presynaptic membrane at the synaptic terminal. Which ion is directly responsible for the vesicular release?

A. CL-
B. Na+
C. Ca++

Ans: C

Q10: A patient with a mutation in the superoxide dismutase enzyme with degeneration of cervical and upper thoracic segments of the spinal cord will present with which of th following?

A. Flaccid paralysis in right lower limb
B. Exaggerated right knee jerk
C. Loss of pain and temperature in upper limbs
D. Loss of fine touch in upper limbs

Ans: B

Q11: Damage to the parasympathetic nucleus of the third cranial nerve will present with which one of the following symptoms?

A. Pupillary dilatation
B. Pupillary constrictions
C. Ptosis

Ans: A

Q12: A patient suffers with a stroke in the pons in the blue area (right side) shown in the attached figure. He will present with which one of the following clinical signs?

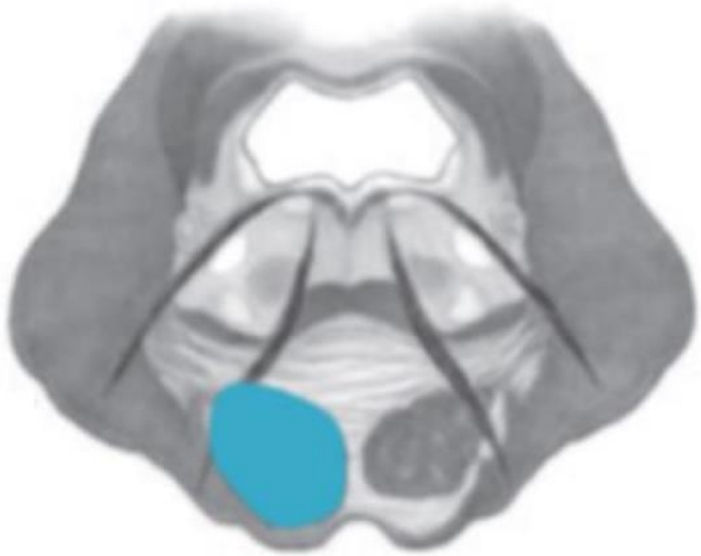

A. Right sided spastic paralysis
B. Left eye deviating down and out
C. Right sided facial paralysis
D. Right eye deviating inwards
E. Right eye deviating down and out

Ans: D

Q13: A case about a patient that presents with a mass that extends across the corpus callosum. Biopsy of mass shows Pseudo-palisading cells. Which of the following neoplasms is most likely present in this patient?

A. Malignant melanoma
B. Pilocytic astrocytoma
C. Medulloblastoma
D. Glioblastoma

Ans: D

Q14: How does acupuncture provide relief from pain according to the gate control theory?

A. By decreasing the activity of A-delta fibers
B. By increasing the transmission of pain signals through C fibers

C. By activating A-beta fibers and substantia gelatinosa

Ans: C

Q15: A patient with mutation in the superoxide dismutase enzyme will present with degeneration of which one of the following structures in the spinal cord?

A. Posterior grey horn cells
B. Spinothalamic tract
C. Anterior grey horn cells
D. Dorsal column tracts

Ans: C

Q16: An old, agitated man is brought to ER because he is unable to effectively communicate. His frustration stems from the fact that he is not comprehensible to anyone. He doesn't understand the doctor questions, does not follow oral or written instructions and cannot repeat phrases. Occlusion of which of the following is responsible for the patients conditions.

A. Anterior inferior cerebellar artery
B. Posterior cerebral artery
C. Middle cerebral artery
D. Posterior inferior cerebellar artery
E. Anterior cerebral artery

Ans: C

Q17: (A long case about a patient) Which of the following receptors initiates the Knee-jerk Reflex?

A. Pacinian corpuscles
B. Golgi tendon organ
C. Muscle spindle
D. Nociceptor

Ans:C

Q18: What is the primary function of anterograde axonal transport in neurons?

A. To transmit electrical impulses from the dendrites to the axon terminal
B. To recycle neurotransmitter receptors back to the cell body
C. To transport waste materials from the synapse to the cell body for degradation
D. To convey synaptic vesicles from the cell body towards the axon terminal

Ans: D

Q19: Which component of the gamma loop is responsible for ensuring that muscle spindles remain responsive to changes in muscle length and contribute to maintaining muscle tone?

A. Golgi tendon organs
B. Alpha motor neurons
C. Interneurons
D. Gamma motor neurons

Ans: D

Q20: Which of the following describes the neutralization of glutamate in the synaptic cleft?

A. Destruction of glutamate by glutaminase.
B. Rapid uptake of glutamate by the presynaptic neuron and astrocytes.

Ans: B

Q21: A very long case about a 68-year-old man that has several diseases including DM, Hypertension, and Ischemic cardiomyopath. The patient suffered a stroke and undergoes carotidangiography. During the procedure atherosclerotic debris embolizes the artery shown (Red arrow). Which of the following actions most likely be impaired?

A. Speaking
B. Gripping
C. Climbing stairs
D. Whistling

Ans.: C

Q22: A heroin addict is brought to ER in an anxious and agitated state. He has nausea, diarrhea, and hasn't been able to sleep for the past few days. His pupils are dilated on examination. What drug can be used to treat his Acute Presntation?

A. Naloxone
B. Aspirin
C. Lidocaine
D. Pentazocine
E. Morphine

Ans: E

Q23: A 70 year old patient with a 20 year history presents with right sided weakness and urinary incontinence. On examination, muscles strength is ⅘ in the right upper extremity and ⅕ in the right lower extremity, and Babinsk sign is present on right side. Sensation is decreased throughout the right foot and leg. Which of the following arteries is most likely to be occluded?

A. Left middle cerebral artery
B. Right anterior cerebral artery
C. Left anterior cerebral artery
D. Right middle cerebral artery

Ans: C

Q24: A Patient with malignant hyperthermia. Which therapeutic agent should be avoided to prevent triggering this potentially life-threatening condition?

A. Thiopental
B. Fentanyl
C. Propofol
D. Sevoflurane
E. Ketamine

Ans: D

Q25: A 45-year-old patient with a history of substance abuse is scheduled for surgery. Which anesthetic agent should be cautiously chosen to minimize the risk of psychomimetic effects and hallucinations in this individual?

A. Isoflurane
B. Fentanyl
C. Midazolam
D. Propofol
E. Ketamine

Ans: E

Q26: Which one of the following parasympathetic ganglion supplies the lacrimal gland?

A. Ciliary
B. Submandibular
C. Pterygopalatine
D. Trigeminal
E. Otic

Ans.: C

Q27: Medial part of the right crus cerebri is damaged, patient will present with which one the following clinical signs?

A. Loss of vibration sensation on the left side of the body
B. Paresis of the lower half of the left side of face
C. Up going planters in the right foot
D. Paresis of the right side of the body

Ans: B

Q28: A case about an 80-year old patient who suffered a car accident with a whiplash type of injury, With which one of the following clinical signs will he present?

A. Loss of fine touch in both lower limbs bilaterally
B. Weakness in both upper limbs
C. Spastic type of paralysis affecting the lower limbs bilaterally
D. Loss of vibration in both lower limbs
E. Flaccid type of paralysis affecting the lower limbs bilaterally

Ans: B

Q29: A Long case about an old male having Wet, wacky, and wobbly signs. Diagnosis of Normal pressure hydrocephalus is done. What is the commonly accepted pathophysiology mechanism thought to be in Normal Pressure Hydrocephalus?

A. Decreased absorption of CSF
B. Increased production of cerebrospinal fluid (CSF)
C. Obstruction of cerebral aqueduct

Ans: A

Q30: In an experiment on neurons from the CNS, the researcher notes that the application of neurotransmitter X to the area around the soma virtually eliminates all action potentials generated by the neuron. Neurotransmitter X is most likely which of the tollowing?

A. Glutamate
B. Acetylcholine
C. Glycine
D. GABA

Ans.: D

Q31: An anterior inferior cerebellar artery stroke will result in ischemic damage to which one of the following structures in the brainstem?

A. Facial nerve
B. Pyramids
C. Hypoglossal nucleus
D. Medial lemniscus
E. Medial longitudinal fasiculus

Ans.: A

Q32: When the healthcare provider applies a gentle stretch to the patient's elbow flexor muscle to assess the inverse stretch (inverse myotatic) reflex, which neuron is responsible for transmitting the information to the central nervous system?

A. C fibers
B. delta
C. A beta
D. Ib
E. Ia

Ans.: D

Q33: A patient suffers with a stroke in the brainstem in the blue area (right side) shown in the attached figure. He will present with which one of the following clinical signs

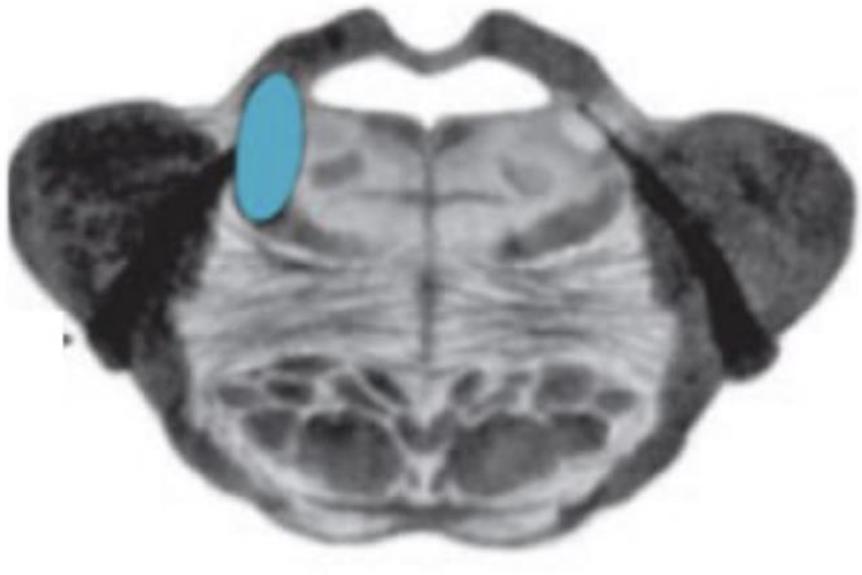

A. Jaw deviates to the left side

B. Left sided spastic type of paralysis
C. Jaw deviates to the right side

Ans.: C

Q34: Which of the following axons would be expected to have the greatest conduction velocity?

A. An unmyelinated pain fiber, 30 cm long, 1 micron in diameter
B. A myelinated fiber from skin mechanoreceptors, 10 cm long, 10 microns in diameter
C. A myelinated motor fiber, 15 cm long, 15 microns in diameter

Ans: C

Q35: A patient presents with reduced tactile discrimination and perception of the light touch in the affected areas. What type of sensory receptor is the most likely affected?

A. Meissner's corpuscle
B. Free nerve ending
C. Ruffini ending
D. Pacinian corpuscle
E. Hair receptors

Ans: A

Q36: A patient came with the fracture of T4 vertebra and right hemisection of the corresponding spinal cord segment. This patient will present with which one of the following clinical signs?

A. Spastic paralysis in the left knee
B. Up going planters in the left foot
C. Loss of pain in the right leg
D. Exaggerated left knee jerk.
E. Loss of temperature in left leg.

Ans: E

Q37:What role do Schwann cells play during axon regeneration in the peripheral nervous system?

A. They degrade the myelin sheath to prevent remyelination
B. They guide axonal regrowth with their basal lamina

Ans: B

Q38: Which of the following statements accurately describes the embryology of neural tube defects?

A. Neural tube defects occur due to abnormal formation of the ectoderm.
B. Neural tube defects result from the failure of neural folds to fuse.

Ans.: B

Q39: Which one of the following cranial nerve nuclei is responsible for supplying preganglionic parasympathetic fibers to Parotid gland?

A. Inferior salivatory nucleus
B. Edinger Westphal nucleus
C. Nucleus solitarius
D. Superior salivatory nucleus

Ans.: A

Q40: Which of the following is associated with central chromatolysis?

A. Repair
B. Apoptosis
C. Chronic inflammation
D. Acute inflammation
E. Necrosis

Ans: A

Q41: A patient was not able to recognize when his big toe of his right foot is passively moved up and down by the neurologist. Damage to which one of the structures can lead to this neurological sign?

A. Posterior grey horn cells
B. Spinothalmaic pathway
C. Anterior grey horn cells
D. Dorsal column tract
E. Corticospinal tract

Ans: D

Q42: The release of which neurotransmitter is associated with the activation of nociceptors?

A. Glutamate
B. GABA

C. Acetylcholine
D. Dopamine
E. Serotonin

Ans: A

Q43: A 55-year-old man visits the physician because he has had a foot ulcer for 2 months that has not healed. There is a symmetric decreased sensation in the distal regions to the lower extremities. The patient has a history of multiple urinary tract infections. due to incomplete emptying of the urinary bladder. He is also impotent. Which of the following pathologic findings is most likely to be present in the peripheral nerves of this patient?

A. Acute inflammation
B. Axonal neuropathy
C. Perivenular lymphocytosis
D. Wallerian degeneration

Ans: B

Q44: A girl's arm is internally rotated, and forearm is pronated with arist flexed (Waiter's Tip). There is no movement in right shoulder and biceps but hand movements are intact.
Which of the following nerve roots of the brachial plexus are most likely affected?

A. C7-C8
B. C5-C6
C. C8-T1

Ans: B

Q45: Which of the following muscles would most likely show signs of weakness in Electromyography (EMG) in a patient with confirmed axillary nerve injury?

A. Deltoid
B. Supraspinatus
C. Biceps brachi

Ans: A

Q46: A patient suffered a brainstem stroke and presents with loss of vibration sense on the left side of the body. Which one of the following structures is involved in this case?

A. Nucleus solitarius

B. Right lateral spinothalamic tract
C. Spinal trigeminal nucleus
D. Medial lemniscus

Ans: D

Q47: A 25-year-old man, a known heroin addict, is brought to the emergency department by police in an anxious and agitated state. He had been in police custody for the last three days. He is complaining of severe body aches, abdominal cramping, nausea, diarrhea, and inability to sleep for the last two days. On examination, his pupils are dilated. After treating the acute presentation, which one of the following drugs will be most effective in treating this patient's heroin ADDICTION?

A. Naloxone
B. Morphine
C. Fentanyl
D. Pentazocine
E. Methadone

Ans: E

Q48: A patient presents with saddle type of anesthesia, loss of bowel and urinary control with radiating pain in the back of his right thigh. What is the diagnosis?

A. Cauda equina syndrome
B. Anterior cord syndrome
C. Syringiomyelia

Ans: A

Q49: Which of the following in embryological development would give rise to the ventral part of the spinal cord Which of the following locations within the embryo corresponds with the gray matter in the ventral part of the spinal cord?

A. Sulcus limitans
B. Alar plate
C. Neural crest
D. Basal plate

Ans: D

Q50: A patient underwent surgery for aortic aneurysm at the level of T7 vertebra. During surgery he suffered cord ischemia. He will present with which one of the neurological signs?

A. Loss of temperature sensation in both lower limbs
B. Exaggerated biceps jerk bilaterally
C. Loss of vibration sensation in both lower limbs
D. Spastic type of paralysis in both upper limbs
E. Loss of pain sensation in both upper limbs

Ans: A

Q51: Which of the following is the effect of mu (opioid) receptor activation on the pre-synaptic neuron terminal in the dorsal horn of spinal cord?

A. Increased release of glutamate
B. Closure of voltage-gated Ca++channels
C. Opening of K+ channels

Ans: B

Q52: A long case about an athlete that injured his ankle. What type of graded potential is likely generated in the peripheral receptors of the injured ankle in response to the painful stimulus?

A. Receptor potential
B. Action potential
C. Excitatory postsynaptic potential (EPSP)
D. Inhibitory postsynaptic potential (IPSP)

Ans: A

Q53: A young child presents with headaches. MRI Scan shows enlargement of Lateral Ventricles and Third ventricles and a Mass on the root of the fourth ventricle. CSF shows High protein. Which of the following is the most likely cause?

A. Oligodendroglioma
B. Brain abscess
C. Glioblastoma
D. Ependymoma

Ans: D

Q54: Pain and temperature sensations from the face are transmitted to which one of the following grey matter columns in the brainstem.

A. General Somatic Efferent
B. Special Somatic Afferent

C. General Somatic Afferent
D. Special Somatic Afferent
E. General Visceral Afferent

Ans: B

Q55: An anterior spinal artery stroke will result in ischemic damage to which one of the following?

A. Inferior cerebellar peduncle
B. Hypoglossal nucleus
C. Vestibular nuclei
D. Spinal trigeminal nucleus
E. Spinothalamic pathway

Ans: Both B and E were considered correct

Q56: Which of the following is the rate-limiting reaction of catecholamines biosynthesis?

A. the conversion of tyrosine to dopamine
B. the reaction catalyzed by tyrosine hydroxylase
C. the conversion of L-Dopa to dopamine

Ans: B

Q57: A patient with tertiary syphilis presented with ataxic gait and absent knee jerk. The ataxic gait in this patient is due to damage to which one of the following structures?

A. Anterior spinocerebellar tract
B. Fasciculus gracilis
C. Posterior spinocerebellar tract
D. Vestibular nuclei
E. Cerebellum

Ans: B

Q58: Aquaporin-1 channels are predominantly located in which of the following structures involved in CSF circulation?

A. Ependymal cells
B. Arachnoid mater
C. Choroid plexus

Ans: A and C both accepted

Q59: Right medial midbrain stroke will result in which one of the following clinical signs?

A. Left sided paresis and right eye deviated inwards.
B. Left sided paresis and right eye deviated down and out.
C. Right sided paresis and left eye deviated down and out.

Ans: B

Q60: T4 vertebrae corresponds to which spinal cord segment?

A. T6
B. T7
C. T3
D. T10
E. T5

Ans: A